



PATIENT

Alex P Kitten Webber

SPECIES

Feline

BREED

DSH

SEX

Male Neutered

AGE

15 years

WEIGHT

10.6lbs

INTERPRETED BY

Maggie Machen Lamy,
DVM, DACVIM
(Cardiology)

IMAGING PERFORMED BY

Dr. Karen Ebersole

HOSPITAL NAME

Scanvet

REFERRING VET

Dr. Bailey

INVOICE

25448

DATE

7/20/22

PRESENTING CLINICAL SIGNS

History: Previously diagnosed with an arrhythmia 11/2021. ECG done at that time reported sinus bradycardia (HR 136) with single VPCs. Left anterior fascicular block noted. Gabapentin 50mg PO for sedation.

Abnormal PE/Chem/CBC/UA Results: PE: no murmur auscultated CBC/Chem/T-4/ProBNP (5/24/22): BUN 39, T-4 2.0, ProBNP 196.

ELECTROCARDIOGRAPHIC FINDINGS

A six lead ECG is available at 100mm/s; 40mm/mV. The average heart rate is 170bpm with a largely regular rhythm. Significant motion artifact throughout. P for every QRS complex and vice versa. The P wave morphology is positive with a normal dimension. Normal PR. The QRS is inverted, consistent with an LAFB. MEA is shifted left. No ectopic beats, pauses or dysrhythmias observed.

ECG diagnosis: Normal sinus rhythm with an LAFB.

ECHOCARDIOGRAM FINDINGS

2D, m-mode, color flow and doppler imaging is available. The left ventricular wall is normal in dimension with endocardial fibrosis and remodeling. There is a diffusely hyperechoic endocardium. The papillary muscles appear mildly remodeled. No hypertrophy seen. The LV chamber is normal with adequate function. The left atrium is mildly dilated. The mitral valve is normal in structure and mobility. No MR. The right atrium is mildly dilated (subjective). The right ventricle is normal. No TR. Normal velocity. Blood flow through both the LVOT and RVOT are normal in velocity. No aortic or pulmonic insufficiency. No pleural or pericardial effusion seen. No obvious cardiac tumors.

CARDIAC CHART

FELINE CARDIAC PARAMETERS	BODY WEIGHT (kg)	HR (BPM)	IVSd (cm) <small>(Moise, Pipers)</small>	LVIDd (cm) <small>(Moise, Pipers)</small>	LWVd (cm) <small>(Moise, Pipers)</small>	FS (%)	EF (%)
NORMAL PARAMETER	-----	150-240	0.35-0.55	<2 (mean 1.5)	3.5-0.55	35-67	80-100
PATIENT	4.8	142	0.47	1.4	0.38	61	92
FELINE CARDIAC PARAMETERS	LA/AO <small>(Boon)</small>	LA/AO HEART BASE (Swe) <small>(Abbott)</small>	LA 2D short axis Base view (cm) <small>(Abbott)</small>	LVOT VEL <small>(m/s)</small>	RVOT VEL <small>(m/s)</small>	E max <small>(m/s)</small>	
NORMAL	<1.5	<1.3	<1.2	<1.6	<1.3	<0.9	
PATIENT	1.36	1.4	1.35	0.9	0.9	NM	
<p><i>*Note: All measurements based upon multi-modal images and methods. An average value is reported.</i> Adapted from June Boon, Veterinary Echocardiography, 1998 Abbott J & MacLean H JVIM 2006;20: 111-119, Moise et al. Am J Vet Res 47:1476, 1986. Pipers et al. Am J Vet Res 40:882, 1979.</p>							

INTERPRETATION OF THE FINDINGS & FURTHER RECOMMENDATIONS

Early unclassified/restrictive cardiomyopathy is suspected. This diagnosis is based upon mild biatrial enlargement with a lack of significant LV thickening/pathology. Many cats with cardiomyopathy will remain occult/asymptomatic for extended periods of time, however there is



PATIENT

Alex P Kitten Webber

a subset that will experience more rapid progression to clinical signs in the first few years after diagnosis. Fortunately, with only mild atrial dilation the risk for complication is low, however there is high risk for progression going forward. No additional issues are identified.

SPECIES

Feline

The ECG shows an LAFB (left anterior fascicular block) as was previously documented. This is a benign conduction abnormality that will persist lifelong. No VPCs are appreciated and previously noted bradycardia is less apparent. Consider possible underlying causes for bradycardia, such as high vagal tone.

BREED

DSH

Given only mild atrial dilation, no medications are indicated at this time. Monitor for any signs of progressive heart disease at home including change in breathing rate or effort, signs of a blood clot event and/or lethargy/syncope going forward.

SEX

Male Neutered

Anesthetic risk is considered mildly elevated, with risk for fluid overload, spontaneous CHF, hypotension, etc. Judicious IV fluid rates are advised to avoid fluid overload. Drugs that stimulate heart rate should be avoided unless clinically necessary (glycopyrrolate, atropine). Avoid ketamine, telazol, acepromazine and Dexdomitor. A reasonable protocol would include opioid/benzodiazepine pre-medication, propofol induction, isoflurane gas. If fluid or steroid therapy is needed, close monitoring of breathing rates is advised as fluid intolerance is certainly a possibility.

AGE

15 years

WEIGHT

10.6lbs

PLAN

Baseline BP is recommended.

INTERPRETED BY

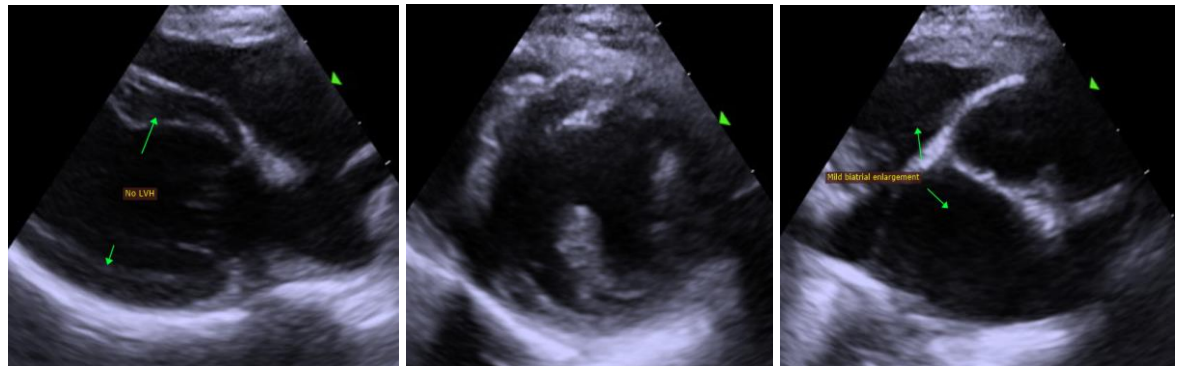
Maggie Machen Lamy,
DVM, DACVIM
(Cardiology)

Recommend recheck echocardiogram in 6 months to screen for progression, sooner if clinical signs arise.

IMAGING PERFORMED BY

Dr. Karen Ebersole

IMAGES



HOSPITAL NAME

Scanvet

REFERRING VET

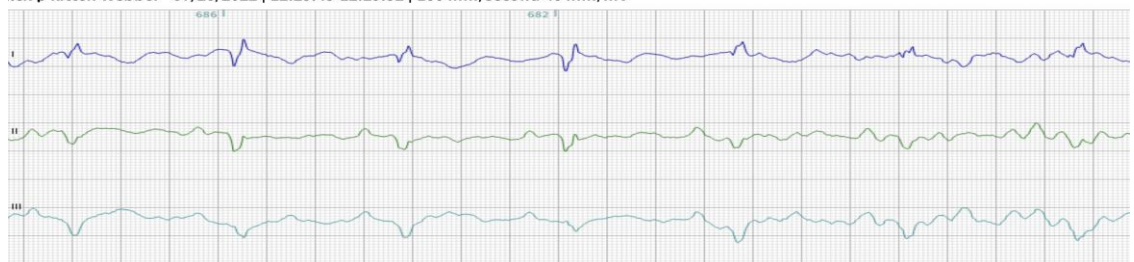Dr. Bailey

INVOICE

25448

DATE

7/20/22





PATIENT

Alex P Kitten Webber

The information and recommendations provided are based on the images presented by the referring veterinarian. No evaluation can be communicated regarding pathology that was not visible in the image/video clips provided.

SPECIES

Feline

Thank you for this referral. This report was generated using transcription software, and minor dictation errors may be present. If the clinical or image interpretation does not parallel your findings or if I can be of any further assistance, please contact me.

BREED

DSH

Maggie Machen Lamy, DVM
Diplomate of the American College of Veterinary Internal Medicine (Cardiology)
info@sonopath.com

SEX

Male Neutered

AGE

15 years

WEIGHT

10.6lbs

INTERPRETED BY

Maggie Machen Lamy,
DVM, DACVIM
(Cardiology)

**IMAGING
PERFORMED BY**

Dr. Karen Ebersole

HOSPITAL NAME

Scanvet

REFERRING VET

Dr. Bailey

INVOICE

25448

DATE

7/20/22